

Case report

## Laparoscopic transgastric removal of eroded adjustable band: a novel approach

Nicole R. Basa, M.D.<sup>a</sup>, Erik Dutson, M.D.<sup>a</sup>, Catherine Lewis, M.D.<sup>a</sup>, Marvin Derezin, M.D.<sup>b</sup>,  
SooHwa Han, M.D.<sup>a</sup>, Amir Mehran, M.D., F.A.C.S.<sup>a,\*</sup>

<sup>a</sup>Section of Minimally Invasive and Bariatric Surgery, University of California, Los Angeles, David Geffen School of Medicine, Los Angeles, California

<sup>b</sup>Division of Gastroenterology and Digestive Diseases, University of California, Los Angeles, David Geffen School of Medicine, Los Angeles, California

Received May 10, 2007; revised December 5, 2007; accepted December 26, 2007

### Abstract

Gastric erosion is a well-known complication of laparoscopic adjustable gastric band (LAGB) placement for morbid obesity. We describe a novel approach for the removal of an eroded band through a laparoscopic gastrotomy with subsequent intraluminal division and removal of the band. A 67-year-old woman with a body mass index of 35.5 kg/m<sup>2</sup> was seen 1 year after LAGB placement performed outside the United States. She had developed dysphagia and regurgitation of undigested food a few months after the procedure. The LAGB had been adjusted twice by her primary surgeons and was completely deflated once her symptoms began. The patient failed to improve and was subsequently referred to our institution where an upper endoscopy revealed intragastric band erosion. The patient was taken to the operating room for LAGB removal; however, standard laparoscopic and endoscopic attempts at band retrieval were unsuccessful. We then attempted a novel laparoscopic technique. An anterior gastrotomy was created, distal to the area of erosion, to facilitate easy intraluminal band division and removal. The gastrotomy was repaired, and a leak test was performed. A postoperative Gastrografin upper gastrointestinal series showed no extravasation. The patient began a diet, was discharged, and was seen in follow-up with complete resolution of her symptoms. The results of this case have shown that laparoscopic transgastric removal of an eroded gastric band is safe and feasible when standard endoscopic and laparoscopic techniques fail. (*Surg Obes Relat Dis* 2008;4:194–197.) © 2008 American Society for Metabolic and Bariatric Surgery. All rights reserved.

**Keywords:** Gastric erosion; Laparoscopic adjustable gastric band; Band removal; Lap band; Band erosion

Gastric erosion is a well-known complication of the laparoscopic adjustable gastric band (LAGB) procedure for the treatment of morbid obesity. Occurring in .5–11% of cases [1–3], it is uniformly agreed that LAGB erosion requires its removal. Many endoscopic and surgical tech-

niques have been described for this purpose. The laparoscopic approach typically includes meticulous dissection of the lesser curve of the stomach, which due to band erosion, commonly adheres to the undersurface of the liver [4]. These often dense adhesions pose a greater risk of gastric and liver injury with dissection. Furthermore, because of the thickened, inflamed nature of the gastric wall, repaired gastrotomies are more prone to leakage and breakdown. We propose a novel approach to this problem in patients in whom the eroded LAGB cannot be retrieved using either conventional endoscopic or laparoscopic methods. In this technique, an eroded LAGB can be excised using laparoscopic gastrotomy with intraluminal division and removal

The video format was presented at the Plenary Session of the American Society for Bariatric Surgery Conference, Thursday, June 14, 2007

\*Reprint requests: Amir Mehran, M.D., F.A.C.S., Section of Minimally Invasive and Bariatric Surgery, University of California, Los Angeles, David Geffen School of Medicine, 10833 Le Conte Avenue, 72-266 CHS, Los Angeles, CA 90095.

E-mail: [amehran@mednet.ucla.edu](mailto:amehran@mednet.ucla.edu)

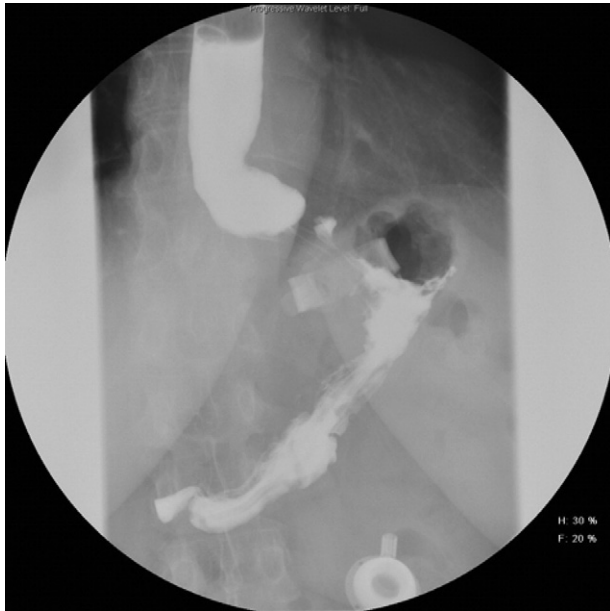


Fig. 1. Preoperative upper gastrointestinal study demonstrating a dilated proximal esophagus and an adjustable gastric band at a slightly slipped position with a questionable intraluminal component.

of the LAGB. To our knowledge, this is the first reported case of its kind in English language studies.

### Case report

A 67-year-old woman with a body mass index of 35.5 kg/m<sup>2</sup> was seen at our clinic 1 year after LAGB placement that had been performed outside the United States. Her medical and surgical histories were unremarkable, except for steroid use for chronic uveitis. According to her history, she had initially done well after the LAGB procedure, although she experienced minimal weight loss, which prompted adjustment of the LAGB by her primary surgeons on 2 occasions. Eventually, she developed symptoms of dysphagia and regurgitation of undigested food, for which her surgeons completely deflated the LAGB. The outside evaluation included a reportedly negative upper endoscopy and upper gastrointestinal imaging studies. She was referred to our program, where she underwent physical examination with normal findings and no evidence of port site infection. The upper gastrointestinal imaging studies and upper endoscopy were repeated, both of which demonstrated intra-gastric erosion of the LAGB (Figs. 1 and 2).

The patient was taken to the operating room where a combined laparoscopic and endoscopic approach was undertaken. The laparoscopic view of the LAGB, as well as of the tubing leading to it, was completely obscured by exceptionally dense adhesions and a large amount of adherent omentum between the lesser curvature of the stomach and the liver. Several endoscopic attempts at LAGB removal

were made using scissors, heat probes, and blades; none of which were successful.

As a final alternative to avoid laparotomy, a laparoscopic gastrotomy was created distal to the eroded band (Fig. 3) to allow for transgastric laparoscopic visualization of the band. Once the eroded band was clearly identified, it was securely grasped, cut using laparoscopic scissors, and removed en bloc (Fig. 4), after dividing the attached tubing (Fig. 5). The gastrotomy was subsequently closed in 2 layers (Fig. 6), and a leak test was performed using both methylene blue and air. The lesser sac was then entered to visualize the posterior gastric wall, which was intact. Finally, despite the negative leak tests, the superficial gastric tissue where the LAGB was presumed to have been was reinforced using an omental patch, and the subcutaneous port was removed. A postoperative upper gastrointestinal imaging study demonstrated no evidence of leak; thus, her diet was slowly advanced. She was discharged and seen later in follow-up with complete resolution of symptoms.

### Discussion

Gastric erosion is a well-known complication of the LAGB and occurs in .5–11% of patients [1–3]. Early erosions have been reported a few days or weeks after the procedure and have been attributed to perforation of the esophagus or the stomach owing to inadvertent injury at the initial placement. If a gastric or esophageal perforation occurs at band placement, the injury should be repaired, and band placement delayed until the gastric or esophageal perforation has healed. Late LAGB erosions typically occur 1–2 years after placement and can arise where full-thickness gastrogastric sutures have been placed. Superficial gastrogastric sutures can decrease the incidence of late LAGB erosion [5]. Other causes of late LAGB erosion include pressure necrosis caused by a tight gastrogastric plication over the LAGB buckle, a microperforation leading to a chronic infectious process and later LAGB erosion, devascularization of the stomach during surgery, and immediate postoperative LAGB inflation. The use of nonsteroidal anti-inflammatory drugs, alcohol, and smoking has also been proposed as factors contributing to stomach mucosal irritation and possible perforation.

The clinical symptoms that can alert the surgeon to an eroded LAGB include the inability to regulate the stomach size with inflation or deflation, weight regain, and port site infection. The latter might be the first sign of gastric erosion and results from bacterial migration from the stomach defect to the port site. Band erosion can also cause small bowel obstruction if the band has completely eroded into the lumen of the stomach [6]. In these cases, removal could require an enterotomy at the site of the obstruction.

Multiple methods of band removal have been discussed extensively throughout international studies. Endoscopic methods include removal with conventional endoscopic equipment or with the aid of the Gastric Band Cutter (A.M.I., Agency for Medical Innovation) [7,8]. Lattuada et al. [7] described the

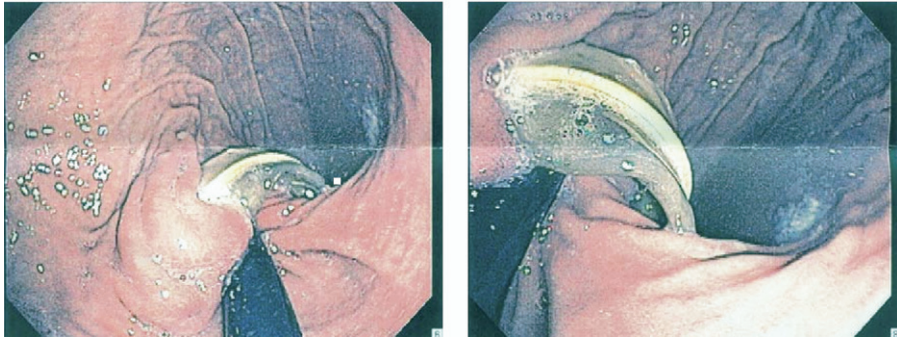


Fig. 2. Endoscopic view of eroded adjustable gastric band.

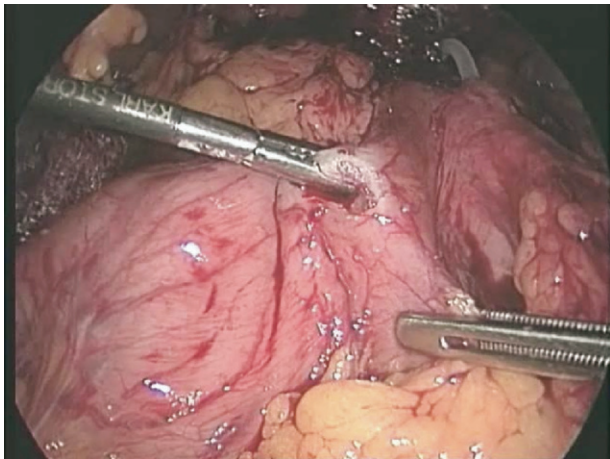


Fig. 3. Laparoscopic gastrotomy.

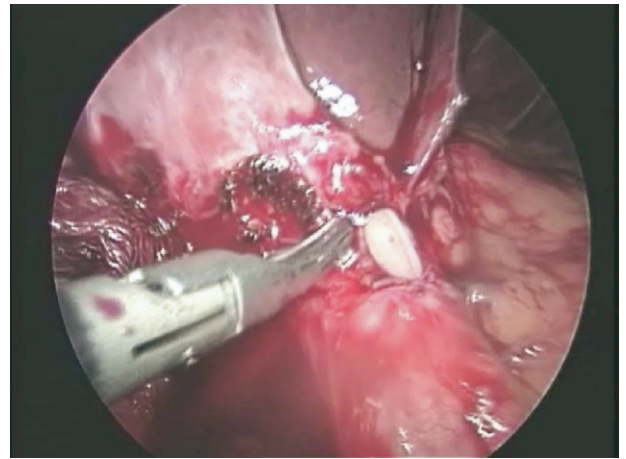


Fig. 5. Infusion catheter attached to the adjustable gastric band demonstrating intrahepatic erosion.

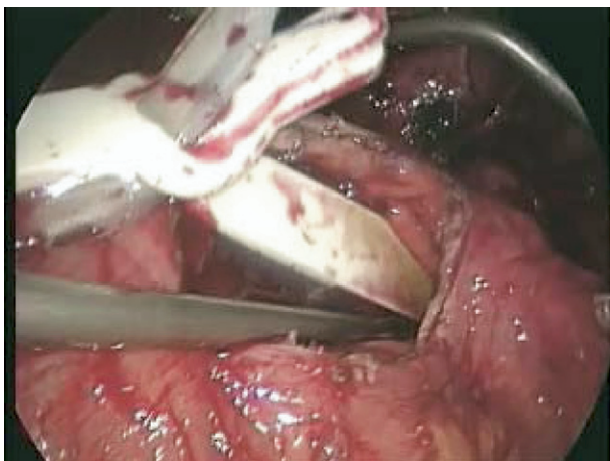


Fig. 4. Adjustable gastric band retrieved from within the stomach lumen.

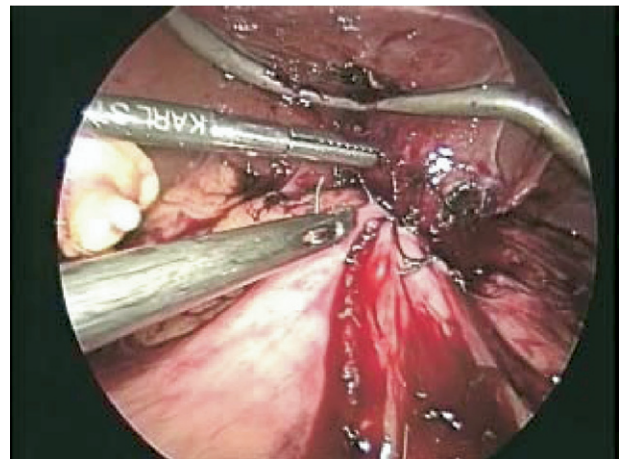


Fig. 6. Gastrotomy repaired in two layers.

successful use of the Gastric Band Cutter in 80% of eroded band cases. Other methods of band removal include perigastric laparoscopic division once the gastrogastic plication has been taken down, open surgery, and an intragastric approach requiring a minilaparotomy and an anterior gastrotomy using flexible endoscopy after the band has been divided [9]. In all cases,

even if solely endoscopic methods are anticipated, it is recommended to perform all techniques in the operating room.

Our case illustrates the first known report of laparoscopic gastrotomy with intraluminal division and removal of a LAGB; however, the laparoscopic transgastric approach has been described for a variety of other pathologic findings

[10–18]. The earliest description in published reports was in 1996 by Geis et al. [10], in which they described a laparoscopic transgastric approach for the resection of benign gastric tumors. Many groups have since modified this technique such that the laparoscopic intragastric resection is performed by way of trocars placed through the abdominal wall directly into the stomach with visualization provided by an endoscope [11–14]. A laparoscopic transgastric approach has also been used to access the biliary tree by way of the remnant stomach in patients who have previously undergone Roux-en-Y gastric bypass [15–17] and has been reported in the removal of an eroded Angelchik prosthesis (a silicone gel-filled implant historically placed around the gastroesophageal junction for the treatment of gastroesophageal reflux disease) [18].

Endoscopic and surgical (laparoscopic and open) techniques for the removal of an eroded LAGB have been extensively described in published reports [5–8]. With the increasing popularity and commercial marketing of various LAGBs, it is plausible to expect more cases of intragastric LAGB erosion. Bariatric and nonbariatric surgeons, therefore, must be familiar with these various extraction methods. The unique approach we have described should provide an additional tool in their armamentarium.

## Disclosures

*The authors have no commercial associations that might be a conflict of interest in relation to this article.*

## References

- [1] Westling A, Bjuling K, Ohrvall M, et al. Silicone adjustable gastric banding: disappointing results. *Obes Surg* 1998;8:467–74.
- [2] Abu-Abeid S, Szold A. Results and complications of laparoscopic adjustable gastric banding: an early and intermediate experience. *Obes Surg* 1999;9:188–90.
- [3] Silecchia G, Restuccia A, Elmore U, et al. Laparoscopic adjustable silicone banding: prospective evaluation of intragastric migration of the Lap-Band. *Surg Laparosc Endosc Percutan Tech* 2001; 11:229–34.
- [4] Abu-Abeid S, Szold A. Laparoscopic management of lap-band erosion. *Obes Surg* 2001;11:87–9.
- [5] Niville E, Dams A, Vlasselaers J. Lap-Band erosion: incidence and treatment. *Obes Surg* 2001;11:744–7.
- [6] Bueter M, Thalheimer A, Fein M. Band erosion and passage, causing small bowel obstruction. *Obes Surg* 2006;16:1679–82.
- [7] Lattuada E, Zappa A, Mozzi E, et al. Band erosion following gastric banding: how to treat it? *Obes Surg* 2007;17:329–33.
- [8] De Palma G, Formato A, Pilone V, et al. Endoscopic management of intragastric penetrated adjustable gastric band for morbid obesity. *World J Gastro* 2006;12:4098–100.
- [9] Silecchia G, Perrotta N, Boru C, et al. Role of minimally invasive approach in the management of laparoscopic adjustable gastric banding postoperative complications. *Arch Surg* 2004;139:1225–30.
- [10] Geis WP, Baxt R, Kim HC. Benign gastric tumors: minimally invasive approach. *Surg Endosc* 1996;10:407–10.
- [11] Privette A, McCahill L, Borrazzo E, et al. Laparoscopic approaches to resection of suspected gastric gastrointestinal stromal tumors based on tumor location. *Surg Endosc* 2008;22:487–94.
- [12] Ludwig K, Wilhelm L, Scharlau U, et al. Laparoscopic-endoscopic rendezvous resection of gastric tumors. *Surg Endosc* 2002;16:1561–5.
- [13] Tagaya N, Mikami H, Kogure H, et al. Laparoscopic intragastric stapled resection of gastric submucosal tumors located near the esophagogastric junction. *Surg Endosc* 2002;16:177–9.
- [14] Vallböhmer D, Hölscher AH. Laparoscopic excision of leiomyomas in the esophageal and gastric wall. *Surg Technol Int* 2007;16: 82–8.
- [15] Nguyen NT, Hinojosa MW, Slone J, Lee J, Khatani V, Wilson SE. Laparoscopic transgastric access to the biliary tree after Roux-en-Y gastric bypass. *Obes Surg* 2007;17:416–9.
- [16] Ceppa FA, Gagné DJ, Papasavas PK, Caushaj PF. Laparoscopic transgastric endoscopy after Roux-en-Y gastric bypass. *Surg Obes Relat Dis* 2007;3:21–4.
- [17] Pimentel RR, Mehran A, Szomstein S, Rosenthal R. Laparoscopy-assisted transgastrostomy ERCP after bariatric surgery: case report of a novel approach. *Gastrointest Endosc* 2004;59:325–8.
- [18] Carbonell AM, Maher JW. Laparoscopic transgastric removal of an eroded Angelchik prosthesis. *Am Surg* 2006;72:724–6.